

FACING YOUR FUNDIC FEARS: EXAMINATION OF THE OCULAR FUNDUS

*J. Seth Eaton, VMD, DACVO
Cornell University Veterinary Specialists*

Approaching the Fundic Examination

The goal of a thorough fundus examination is to clinically evaluate the structures within the eye's posterior segment. In dogs and cats, these structures include:

1. Optic disk (cranial nerve II)
2. Retina (and retinal pigmented epithelium)
3. Tapetum
4. Vasculature
 - a. Retinal vasculature
 - b. Choroidal vasculature

A thorough examination of the fundus can provide valuable clinical information and should be an integral part of the general physical examination. Fundus examination is particularly important when investigating:

1. Vision impairment/blindness
2. Neurologic disease
3. Any systemic and potentially disseminated illness
 - a. Infectious disease
 - b. Immune-mediated disease
 - c. Vascular disease
 - d. Neoplastic disease

Performing a Fundic Examination

There are 3 basic steps used to perform a complete fundic examination. These steps include:

1. Pupil dilation
2. "Wide angle" (lower magnification) examination of the fundus
3. "Zoomed" (higher magnification) of fundic lesions/abnormalities

PUPIL DILATION

Pupil dilation is essential for evaluating the fundus in its entirety and can be easily achieved with topical mydriatic agents. The most commonly employed agents are parasympatholytic drugs such as tropicamide or atropine. These drugs paralyze the smooth muscle of the iris sphincter and allow the pupil to expand. Many ophthalmologists prefer to use **tropicamide** as this drug is shorter-acting than atropine, lasting a maximum of 10-12 hours in dogs and cats. One drop of tropicamide should dilate a normal dog pupil within 30 minutes of administration and a normal cat pupil within 15 minutes. The degree and rapidity of dilation may be enhanced by application of a second drop of tropicamide 5 minutes after the first. **Atropine**, while equally effective in producing dilation, can exert its effect for up to 3-5 days in dogs and cats.

Sympathomimetic drugs such as **phenylephrine** produce pupil dilation by stimulating adrenergic receptors within the iris dilator muscle. While sympathomimetic agents can effectively produce dilation in dogs, they are ineffective in cats.

The primary contraindication for pupil dilation in dogs and cats is known predisposition to glaucoma, as it can reduce the width of the ciliary cleft and iridocorneal angle and obstruct aqueous outflow. It is also noteworthy that eyes with active uveitis (intraocular inflammation) dilate less readily than those without.

LOWER MAGNIFICATION FUNDIC EXAMINATION

A lower magnification or “wide-angle” approach to fundic examination is best achieved using **indirect ophthalmoscopy**. In this technique, a convex lens is positioned between a light source and the observer’s eye and the patient’s eye. This technique provides a low-magnification view of the fundus but permits the observer to see a larger or wider fundic field, allowing a clinician to “scan” the entire fundus for structural abnormalities. It is noteworthy that the image seen is **inverted** and **reversed**. For example, lesions seen dorsomedially are actually located within the ventrolateral fundus.

The list of equipment necessary for indirect ophthalmoscopy includes:

1. A bright light source (Finoff transilluminator, otoscopic light)
2. Indirect ophthalmoscopy lens/lenses

Indirect ophthalmoscopy lenses may refract light differently and are therefore labeled according to their **diopter strength** (i.e. 14D, 20D, 40D). The choice of lens may depend upon the size of fundic field and degree of magnification desired by the observer. The following table illustrates the relationship between lens strength and the image produced.

	14 D Lens	40D Lens
Fundus Magnification	Higher	Lower
Depth Perception (Stereopsis)	Higher	Lower
Facility of Examination Through a Small Pupil	Poor	Good
Field of View	Smaller	Larger

In general, most clinicians prefer a 20D lens for examination of the dog and cats fundus. The Volk® PanRetinal® is an excellent “hybrid” lens providing the magnification of a 20D lens while also providing the wider field of view of a 30D lens.

HIGH MAGNIFICATION FUNDIC EXAMINATION

Direct ophthalmoscopy differs from the indirect technique, both in terms of instrumentation and the image produced. With direct ophthalmoscopy, the image seen is **upright** and magnification is much greater. Field of view, however, is much more limited. High magnification or “zoomed” examination facilitates description and characterization of focal fundic lesions and can also facilitate close examination of the optic disk.

Monocular indirect ophthalmoscopy is a technique made possible by newer instrumentation such as the Welch-Allyn® PanOptic® ophthalmoscope. This produces an upright image of intermediate magnification and field of view when compared to indirect and direct ophthalmoscopy techniques.

Learning the approach to fundic examination can be different for every clinician, as each will become comfortable with certain equipment and techniques based on his or her own experience. The techniques of indirect and direct ophthalmoscopy carry their own advantages and disadvantages, but when used in tandem can provide a comprehensive means of evaluation.

Understanding Fundic Anatomy

When examining the fundus, it is important to remember that the image you observe is a composite of several layers. Understanding the anatomic features and relationships between these layers is a key component to fundus examination and interpretation.

In general, the fundus in dogs and cats can be divided into two regions, the **tapetal** fundus and the **non-tapetal** fundus.

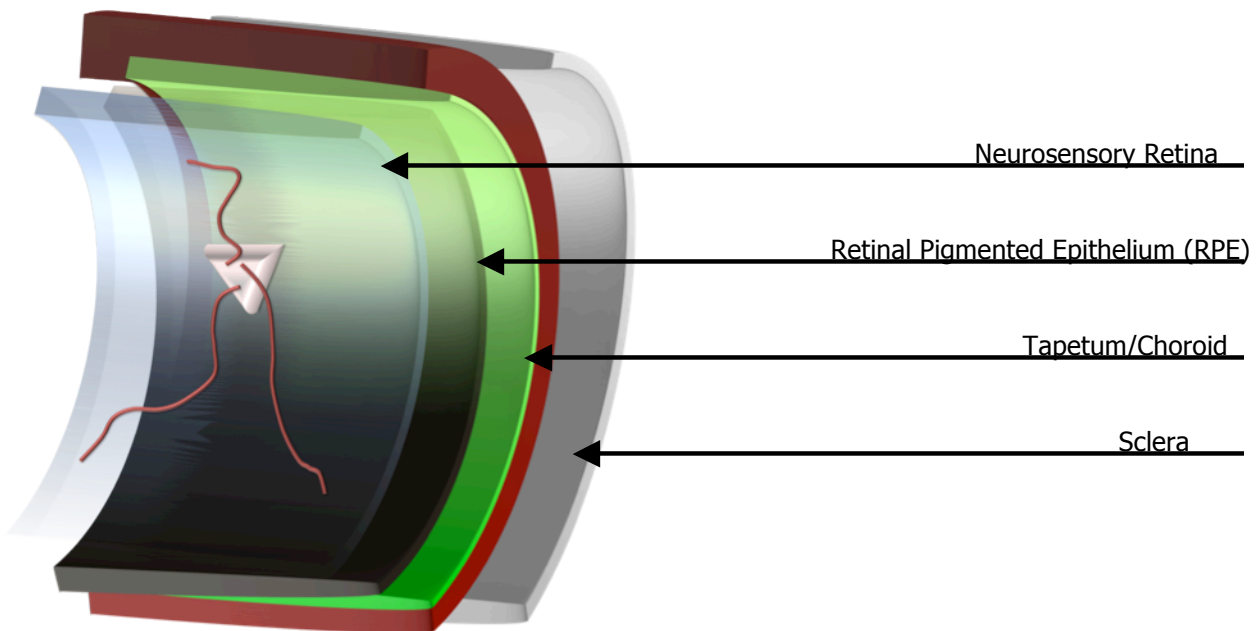
NON-TAPETAL FUNDUS

In dogs and cats, the non-tapetal fundus is primarily inferior to, but also surrounds the tapetal fundus (see below). The most anterior structures (structures closest to the observer) within the non-tapetal fundus are the optic disk and retinal blood vessels. Unless pathology is present, the neurosensory retina should be an essentially transparent structure. The brown **melanin** of the retinal pigmented epithelium (RPE) is therefore the prominent feature within the non-tapetal fundus. In most dogs, the RPE is densely pigmented, obscuring the observer’s ability to see the posterior fundic structures (choroid, sclera).

TAPETAL FUNDUS

Similar to the non-tapetal fundus, the most anterior structures within the tapetal fundus are the retinal blood vessels. In some animals, especially cats, the optic disk resides within the tapetal fundus. In the tapetal fundus, however, the choroid is modified with a highly-reflective anterior cellular layer called the **tapetum**. This layer acts as a

reflective surface, enhancing light stimulation of the retina. The RPE overlying the tapetum is continuous with its pigmented counterpart, but does not contain melanin.



Understanding Fundic Pathology

NORMAL VARIATION

There is a wide variety of “normal variation” in fundic appearance amongst different species, breeds, and even between individual animals. For example, some small-breed dogs (Pugs, Chihuahuas) may have small tapeta, producing relatively large non-tapetal fundic regions. Merle-coated dogs such as Australian shepherds or other dogs or cats with dilute coat color may have no tapetum and little to no pigment within RPE, permitting the observer to see both the choroidal vasculature and sclera. This produces a “tiger-striped” or striated appearance to the fundus.

FUNDIC PATHOLOGY

Ocular pathology involving the posterior segment often cause changes in fundic appearance. Exposure of the sclera may also be seen with non-inflammatory inherited diseases like Collie eye anomaly or merle ocular dysgenesis, due to structural defects such as choroidal hypoplasia or coloboma/staphyloma formation.

Since the neurosensory retina is essentially a transparent membrane, direct observation of pathology can be a challenge. Observation of changes in tapetal reflection, however, can aid the observer in identifying even subtle structural retinal disease. Since the retina resides between the observer and the tapetum (which is part of the choroid), pathology will cause characteristic alterations in tapetal reflection.

Lesions overlying the tapetum can generally be classified as **hyperreflective** or **hyporefective**. **Hyperreflective** lesions are so-named due to atrophy or thinning of the retina and retinal pigmented epithelium. The tapetum's inherently iridescent surface becomes more brilliant and often takes on a "metallic" appearance. In most cases, hyperreflective lesions are representative of inactive disease processes that have resulted in end-stage retinal atrophy (i.e. previous inflammatory insults (chorioretinitis/retinitis), retinal dysplasia, glaucoma, or progressive retinal atrophy).

Hyporefective lesions obscure the observer's ability to view the tapetum. These lesions are usually representative of intraretinal or subretinal edema, cellular infiltrate (leukocytic, granulomatous, hemorrhagic), or even neoplastic infiltration. Hyporefective lesions can be indicative of retinitis or chorioretinitis and are representative of an active disease process. They are very often associated with ocular manifestation of active systemic disease.

FUNDIC EXAMINATION TECHNIQUE

1. Ensure that the examination can be performed in a dimly-lit and quiet examination room
2. Have an assistant restrain the patient, stabilizing the head with the patient's eye level with the your eye. Your assistant should also retract the patient's eyelids.
3. Position yourself 0.5 to 0.75 m from the patient. This is approximately a slightly-bend arm's length.
4. Position your bright light source immediately next to your dominant eye and direct the beam toward the patient's eye.
5. Adjust the position of the light beam until you observe a bright tapetal reflection from the patient's eye.
6. Once a tapetal reflection has been observed, place your indirect ophthalmoscopy lens in from the patient's eye, approximately 2-4 cm from the corneal surface.
NOTE: Most indirect lenses have one etched rim, making it silver in color. This rim indicates which side of the lens should be facing the patient.

**The greatest challenge in performing indirect ophthalmoscopy is maintaining a stable fundic image. To maximize your technique, remember the following rules of thumb.

1. Alignment, alignment, alignment. Keeping yourself and your equipment in alignment with the patient's eye is critical. Imagine that there is a metal rod extending from your light beam and into the patient's eye, and that rod must always go through the center of your indirect lens.
2. The patient **WILL** move their eye. Do not try to "chase" the image when your patient's eye moves. Instead, remove the indirect lens, re-establish your alignment and try again.
3. If you see are trying to see a peripheral lesion within the fundus, *move toward it* to achieve a better view. For example, if you see a lesion that is at the **ventral** aspect of your field of view, move your entire alignment **ventrally** to see it better.